

UNDERSTANDING CERVICAL COLPOSCOPY

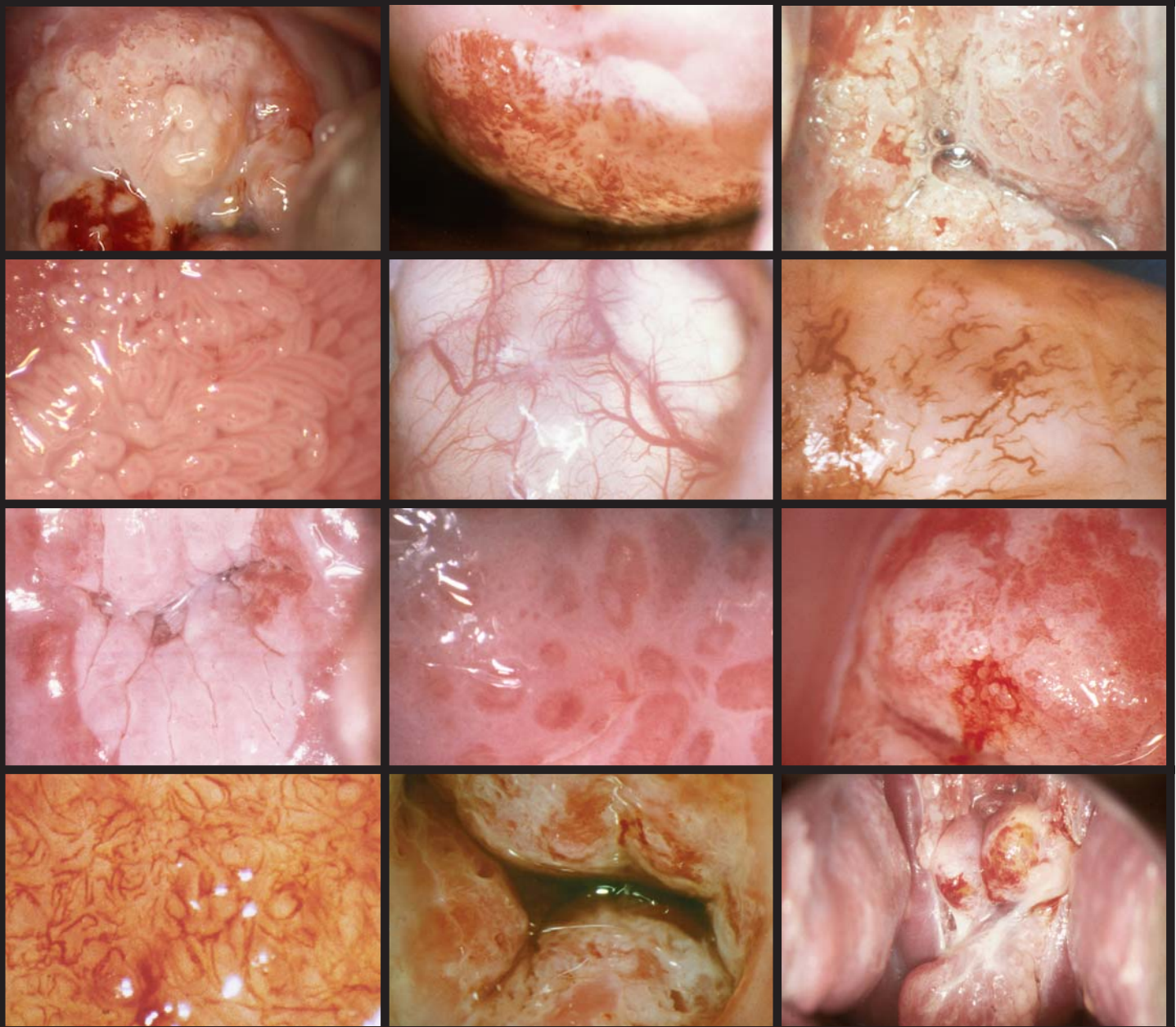
BY ANALYSIS OF
240 TRUE COLPOPHOTOGRAPHS
IN A POWERPOINT® PRESENTATION
ON CD-ROM

by

V. Cecil Wright, MD

\$80.00 USD

**Microsoft® Powerpoint® program not required to view CD-ROM*



CONTENTS

The normal cervix
Native squamous epithelium
Columnar epithelium
Metaplasia - the normal transformation zone
The abnormal transformation zone - cervical intraepithelial neoplasia
The abnormal transformation zone - squamous cell cancer
Glandular lesions - adenocarcinoma in situ and adenocarcinoma
The cervix in pregnancy
Cervical condylomata
Cervical polyps, DES-exposed and other structural abnormalities
Microglandular hyperplasia
Inflammatory conditions
Colposcopy of cervix and vaginal vault after treatment for cervical intraepithelial neoplasia and cancer
"Core Concept" summaries for each topic